

## Detection of some Physiological and Histological changes in laboratory rabbits infected with *Necator americanus* parasite

Maroof Sabti Juma Al-Ammash\*<sup>1</sup>, Marwa Shakir Mahmood Al-Badry<sup>2</sup>, Salah Abed Hasan<sup>3</sup>

<sup>1</sup>Department of Pathological Analysis, Faculty of Applied Science, University of Samarra, Iraq.

<sup>2</sup>Department of Biology, Faculty of Education, University of Samarra, Iraq.

<sup>3</sup>Department of Biology, Faculty of Science, University of Sfax, Tunis.

### ABSTRACT

**Background:** The present study was conducted for the period from February to October 2022 in University of Samarra laboratories.

**Methods:** This study included 20 male laboratory rabbits, whose weight ranged from (1.4-1.5) Kg, ten of them were as a control group and the other ten were infected with *N. americanus* parasite. Some biochemical tests such as lipid profile (HDL, Cholesterol, and Triglycerides) and liver enzymes (GOT and GPT) are examined, as well as tissue sections of the liver, lung and small intestine to see the changes that occur due to infection.

**Results:** The present results showed significant differences for total cholesterol between control and infected groups (88.40 and 71.80) mg/dl, respectively, as for triglycerides, non-significant variances were recorded between control and infected groups (68.80 and 69.80) mg/dl, respectively, whereas for HDL the present results showed significant differences between control and infected groups (27.40 and 22.60) mg/dl, respectively. The current results showed significant increase in concentration of GOT of infected group compared with control group (27.20 and 15.60) mg/dl, respectively, as for GPT, non-significant variances were recorded between infected and control groups (17.80 and 14.60) mg/dl, respectively, while for Iron, significant differences occur between infected and control groups (74.00 and 101.40) mg/dl, respectively. The histological study showed the presence of histological changes in the members infected group that were studied.

**Conclusion:** The occurrence of significant differences in the levels of lipid profiles (cholesterol and HDL) and non-significant differences of triglycerides in infected group compared with control group. The current study recorded significant differences in GOT and Iron, and non-significant differences in GPT of infected group compared with control group. The occurrence of changes in histological sections of liver, lung and intestine of infected group compared with control group.

**KEYWORDS:** *Necator americanus*, Rabbit. Physiological and Histological findings.

### ARTICLE DETAILS

**Published On:**  
02 February 2024

**Available on:**  
<https://ijpbms.com/>

### INTRODUCTION

The Ancylostomidae family includes what are referred to as hookworms. They cling to the mucosa of the host's gut and dwell there, feeding on the blood and bodily fluids that are sucked out of it. Hookworms develop and reproduce in their host's small intestine. Embryos have grown by the time they are passed with feces. It is impossible to identify species that infect humans with certainty from just their eggs. Warmth, shade, and moisture are necessary for the continuing development of eggs. Newly hatched J1s have a rhabditiform esophagus. In two to three days, juveniles shed their cuticle

and live in the feces, where they consume fecal detritus, continue feeding and growing as a rhabditiform esophagus until it molts to the third stage, which can infect a host, after about five days. The hookworm's pointed tail helps distinguish filariform J3s from other types of worms. Living in the upper few millimeters of soil. Freezing or desiccation kills them quickly. Skin fatty acids and heat stimulate penetration behavior (Haas *et al.*, 2005). J3s that come into contact with a host's skin get infected (Roberts *et al.*, 2013). Juveniles are transported from a blood or lymph channel to the heart and subsequently to the lungs. They enter the

## Detection of some Physiological and Histological changes in laboratory rabbits infected with *Necator americanus* parasite

alveolar air gaps and move up the respiratory tree via ciliary activity to the glottis. The small intestine is where they eventually end up after being eaten. There, they connect to the mucosa, develop, and molt to the fourth stage, which has a larger buccal capsule. The sexual development of worms occurs after additional growth. The worms consume a lot of blood (Williamson *et al.*, 2003; Hossain & Bhuiyan., 2016). From the time of infection to the start of egg production, at least five weeks must pass (Roberts *et al.*, 2013).

*Necator americanus*, the "American killer," was first discovered in Brazil and then Texas, but it was later determined that it was actually indigenous to Africa, India, Southeast Asia, China, and the islands in the southwest Pacific. It most likely traveled to the New World on slave ships. The evolution of the southern United States' economy and culture, as well as those of other parts of the world where it exists, has been significantly influenced by the worm. There are no established international surveillance systems that provide precise statistics on the prevalence of hookworm infection, which makes it difficult to implement policies to stop the spread of the parasite (Roberts *et al.*, 2013).

### MATERIALS AND METHODS

The present study was conducted for the period from April to October 2022 in University of Samarra laboratories. The study included 20 male laboratory rabbits, whose weight ranged from (1.4-1.5) Kg, ten of them were as a control group and the other ten were infected with *N. americanus* parasite. Some biochemical tests such as lipid profile (HDL, Cholesterol, and Triglycerides) and liver enzymes (GOT and GPT), as well as tissue sections of the liver, lung and small intestine to see the changes that occur due to infection.

### Microscopic examinations

The microscopic examinations were included direct wet mount method of rabbit feces for detecting of parasitic infection with *N. americanus* (WHO, 1991).

### Determination of Lipid profiles concentration

Estimating lipid profiles concentration in serum by using a commercial kit, equipment from Randox England Company.

### Determination of both GOT and GPT concentrations

GOT and GPT concentrations in serum was estimated by using a commercial kit, equipment from Randox England Company.

### Determination of Iron concentration

Estimating Iron concentration in serum by using a commercial kit, equipment from Biolabo France Company.

### Histological preparations

Histological sections were prepared based on Bancroft and Stevens (1987) method for detecting the histological changes to each Liver, Lung and small intestine.

### Statistical analysis

Data analysis was performed according to the t-test; the means of the groups were measured with  $P \leq 0.05$  and by using the SPSS program (Cleophas and Zwinderman, 2016).

## RESULTS AND DISCUSSION

### Microscopic examinations

The microscopic examinations were included direct wet mount method of rabbit feces by using eosin stain for detecting of parasitic infection with *N. americanus*, look Figure 1

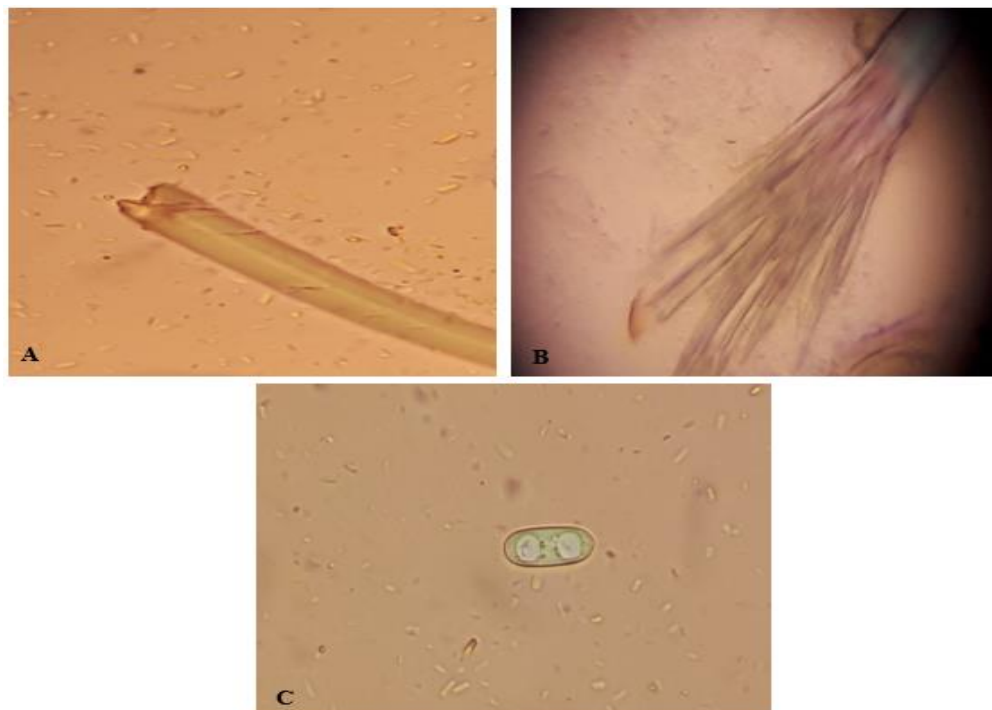


Figure 1: *N. americanus*; (A): Head of adult worm, (B): Tail of adult worm, (C): Egg of the worm  $\times 40$ .

## Detection of some Physiological and Histological changes in laboratory rabbits infected with *Necator americanus* parasite

### Liver's enzymes and Iron

The present results showed (as in table 2) significant increase in concentration of GOT of infected group compared with control group (27.20 and 15.60) mg/dl, respectively, as for GPT, non-significant variances were recorded between infected and control groups (17.80 and 14.60) mg/dl, respectively, while for Iron, significant differences occur between infected and control groups (74.00 and 101.40) mg/dl, respectively.

### Lipid profiles

The present results showed (table 1) significant differences for total cholesterol between control and infected groups (88.40 and 71.80) mg/dl, respectively, as for triglycerides, non-significant variances were recorded between control and infected groups (68.80 and 69.80) mg/dl, respectively, whereas for HDL the present results showed significant differences between control and infected groups (27.40 and 22.60) mg/dl, respectively.

**Table (1): The levels of lipid profiles of each laboratory rabbits infected with *N. americanus* and normal groups**

| Groups<br>Parameters | -ve Ctrl         | +ve Ctrl                    |
|----------------------|------------------|-----------------------------|
|                      | Mean± SD (mg/dl) |                             |
| Total Cholesterol    | 88.40 ± 8.11     | 71.80* ± 5.76               |
| Triglycerides        | 68.80 ± 7.85     | 69.80 <sup>n.s</sup> ± 9.01 |
| HDL-C                | 27.40 ± 2.07     | 22.60* ± 1.34               |

(<sup>n.s</sup>) non-significant different, (\*) significant different

**Table (2): The levels of liver enzymes and Iron of each laboratory rabbits infected with *N. americanus* and normal groups**

| Groups<br>Parameters | -ve Ctrl         | +ve Ctrl                    |
|----------------------|------------------|-----------------------------|
|                      | Mean± SD (mg/dl) |                             |
| GOT                  | 15.60 ± 2.70     | 27.20* ± 4.60               |
| GPT                  | 14.60 ± 2.88     | 17.80 <sup>n.s</sup> ± 3.90 |
| Iron                 | 101.40 ± 11.93   | 74.00* ± 13.56              |

(<sup>n.s</sup>) non-significant different, (\*) significant different

Pierce *et al.* (2019) indicated that both genders with *N. americanus* infection showed dyslipidaemia (higher than normal levels of total cholesterol, triglycerides, LDL, or the total cholesterol/HDL ratio, low HDL), as well as abnormal liver function tests (abnormal alanine transaminase, aspartate transaminase), whereas Umbrello *et al.* (2021) indicated that liver enzymes were normal during the infection with *N. americanus*

Examining the concentrations of two liver enzymes in blood serum helps us to infer the presence or absence of damage or a specific injury (Nelson & Cox, 2008). As the Kaplan, (2000). As for the GPT enzyme, it is present in the liver cells and is present in small quantities in the kidneys, heart, and skeletal muscles. Any damage to the visceral tissue in the liver leads to the release of this enzyme, and thus a rise its concentration (Pagana *et al.*, 2022), In general, any damage that occurs in the liver cells as a result of the invasion of the parasite that possesses some tissue-dissolving enzymes

increase in the concentration of these two enzymes above the normal limit for them (in the blood) indicates the presence of a certain pathological condition (Al-Ammash, 2012). Where the GOT enzyme is present in liver cells, heart muscle, and skeletal muscle cells, and to a lesser extent in the kidney and pancreas, and when the cells of these types of tissues are damaged, the GOT enzyme is released, and its increase depends on the number of damaged cells (Penman *et al.*, 2022), and the GOT enzyme is similar to GPT enzyme, but due to the presence of the first in other tissues, it is not considered specialized for damage to the liver (Pratt & leads to the liberation of the enzyme into the blood and thus an increase in its concentration (Sabaa, 2021).

Heavy infections in malnourished hosts are associated with anemia and protein loss. Protein-losing enteropathies may also result from the inflammatory changes induced by other intestinal hook worms (Wakelin, 1996).

The primary harm caused by hookworms in humans is intestinal blood loss brought on by mature parasites. The

## Detection of some Physiological and Histological changes in laboratory rabbits infected with *Necator americanus* parasite

anemia caused by iron shortage that develops after a moderate to severe infection is referred to as "hookworm illness" in most cases. Blood loss happens when the worms contract their muscular esophagi to create negative pressure, which draws a plug of tissue into their buccal capsules, and then utilize their cutting apparatus to adhere to the intestinal mucosa and submucosa (Hotze *et al.*, 2004). Hemoglobin is released when some red blood cells lyse, by a series of hemoglobinases in the parasite's gut (Williamson *et al.*, 2003).

Depending on the status of host iron, a hookworm burden (i.e., the intensity of infection, or number of worms per person) of 40 to 160 worms is associated with hemoglobin levels below 11 g/dl (Lwambo *et al.*, 1992; Bundy *et al.*, 1995). However, other research has demonstrated that anemia may manifest with a lower hookworm burden (Olsen *et al.*, 1998), depending on the species, hookworms can cause varying degrees of iron-deficiency anemia (Albonico *et al.*, 1998). For instance, in Zanzibar, children with only *N. americanus* infections had a prevalence of hypoferritinemia (ferritin level, <12 µg/liter) of 33.1%, whereas children with both *N. americanus* and *A. duodenale* infections had a prevalence of 58.9% (Stoltzfus *et al.*, 1997). There is a direct relationship between the decline in hemoglobin, serum ferritin, and protoporphyrin levels and the severity of hookworm infection, which is commonly assessed by quantitative egg counts, when the host's iron stores are depleted (Hotze *et al.*, 2004). One of the most significant neglected tropical diseases in humans is hookworm infection, which affects 576-740 million people worldwide and results in intellectual and physical growth retardation as well as iron deficiency anemia (Chang *et al.*, 2020).

### The histological study

#### 1. The liver

The results of this study showed larva of worm among hepatocytes (Fig 1), vacuolated degeneration and necrosis of hepatocytes, infiltration of lymphocytes, fibrinoid and congestion of blood vessel (Fig 2), disappeared of sinusoid (Fig 3).

Some of these findings concur with those of Uduchi *et al.* (2022), who found that *N. americanus* infection in Albino rats led to inflammatory changes, hepatocytic degenerative changes, necrosis, distortion of fragmented hepatocytes, and distortion of fragmented hepatocytes. The liver is known as the major organ of detoxification and biotransformation, Due to its location and blood supply (Uduchi *et al.* 2022). Perhaps

because the location of the liver is close to the lung, the larva may reach the liver during its migration inside the host's body, and this is indicated by current our study, which indicated the presence of the larva within the liver tissue section.

#### 2. The lung

The present study showed diapedesis of lymphocytes, leakage of plasma proteins, congestion of blood vessel and aggregate of lymphocytes (Fig 4), degeneration of alveolar cell, necrosis of alveolar cells (Fig 5) and larva of worm among the lung cells (Fig 6).

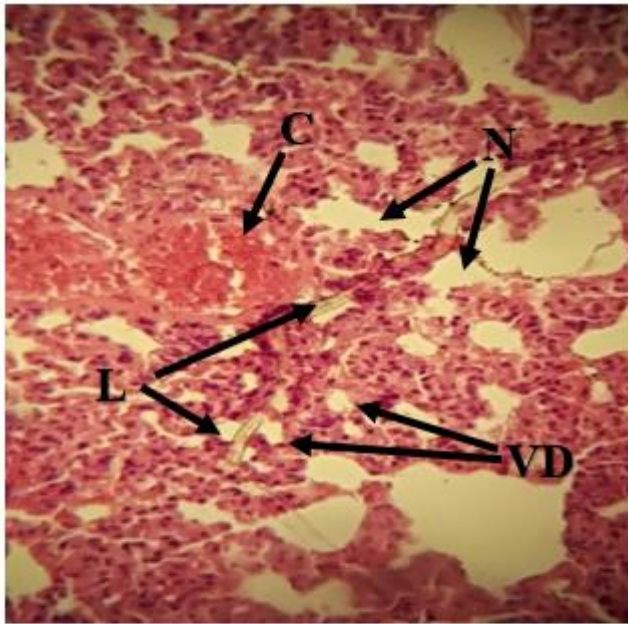
Wilkinson (1990), noted that lung sections from mice infected with *N. americanus* displayed intra-alveolar edema, sections of larvae, and an inflammatory infiltrate primarily consisted of acute inflammatory cells with sporadic lymphocytes and sparse eosinophils in the peri-bronchial region. The larvae were mostly discovered in the previously described tiny bronchi and alveolar ducts, as shown, and they did not appear to have caused any localized cellular inflammation. Infected groups had an increase in the intensity of the cellular inflammatory infiltrate, and eosinophils were seen as a higher proportion of the infiltrate on tissue sections, in addition to the polymorphonuclear leukocytes, lymphocytes, and macrophages that were noticeable with the formation of giant cells in some sites. Although some larvae (or detritus) in the lung parenchyma were surrounded by inflammatory cells, it was also possible to see larvae that had no adhering cells. The peribronchial infiltrate's inflammatory cells surrounding the larvae exhibited the similar variety of cell types. As Wilkinson (1990) indicated to possibly implicating vessel leakage during the earlier stages of infection and in some cases infected mice had observable worms in their alveoli, these were surrounded by collections of inflammatory cells with occasional giant cells.

Migration of larvae after entering the host's body and reaching the lung, which is the normal larval path through which it continues to develop to reach the adult stage after reaching the intestine may cause significant damage to the lung tissue. (Bouchery *et al.*, 2020), In addition, the presence of larvae in the lung tissue was observed, as shown in the results of current our study.

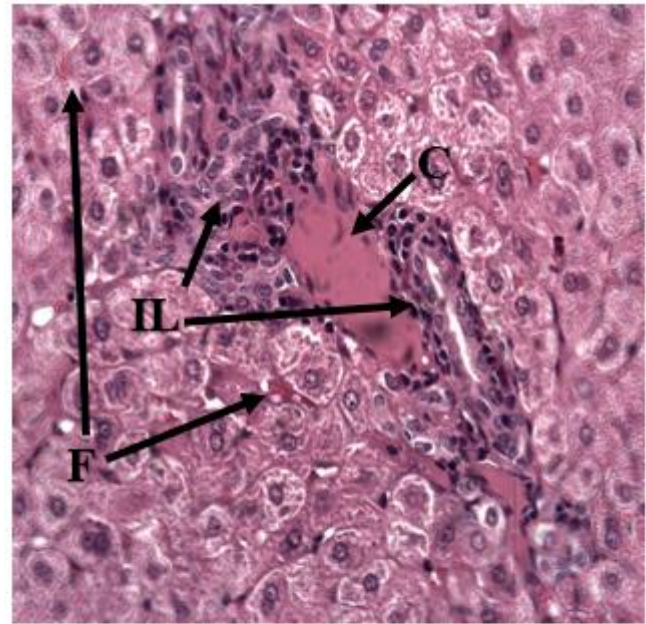
#### 3. The intestine

The current study revealed necrosis in mucosa layer (Fig 7), degeneration in Brunner glands and lamina propria, formation of ghost cells, congestion of blood vessel and atrophy of epithelial layer (Fig 8). Some this findings agree with Uduchi *et al.* (2022) that showed degenerative changes in intestine section.

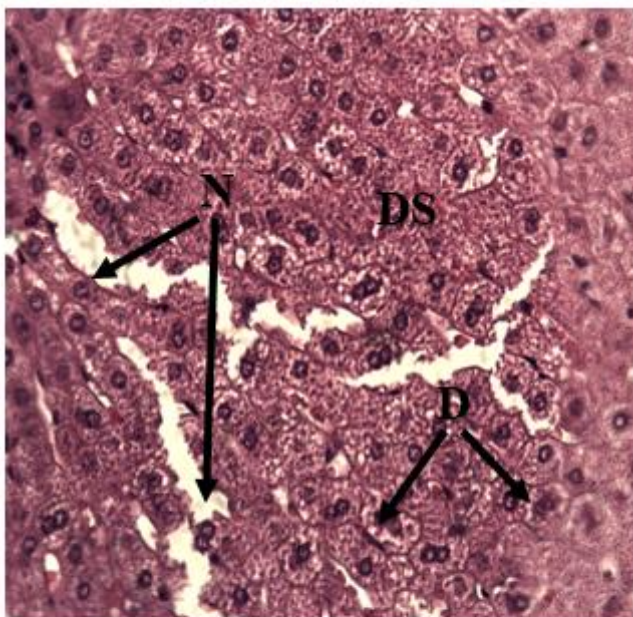
Detection of some Physiological and Histological changes in laboratory rabbits infected with *Necator americanus* parasite



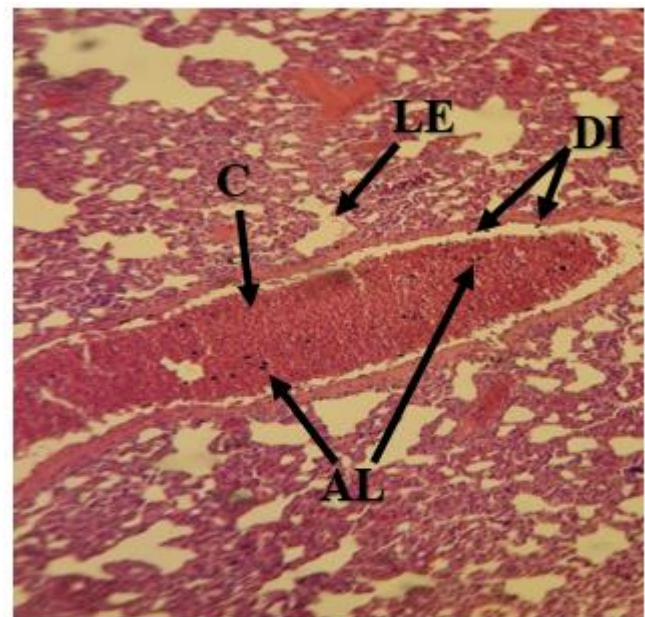
**Figure 1:** Liver section of infected group show Larva of worm (L), vacuolated degeneration (VD) and Necrosis of hepatocytes (N), H&E 100X.



**Figure 2:** Liver section of infected group show Infiltration of lymphocytes (IL), Fibrinoid (F) and Congestion of blood vessel (C), H&E 400X.

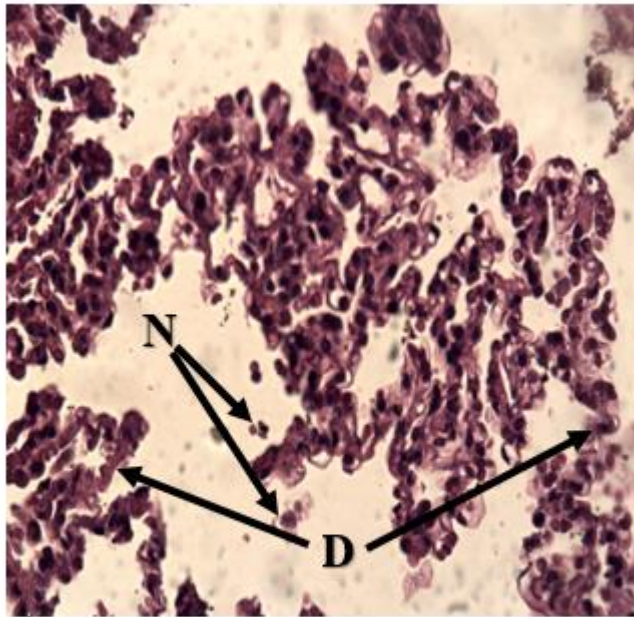


**Figure 3:** Liver section of infected group show Disappeared of sinusoid (DS), Degeneration of hepatocytes (D) and Necrosis of hepatocytes (N), H&E 400X.

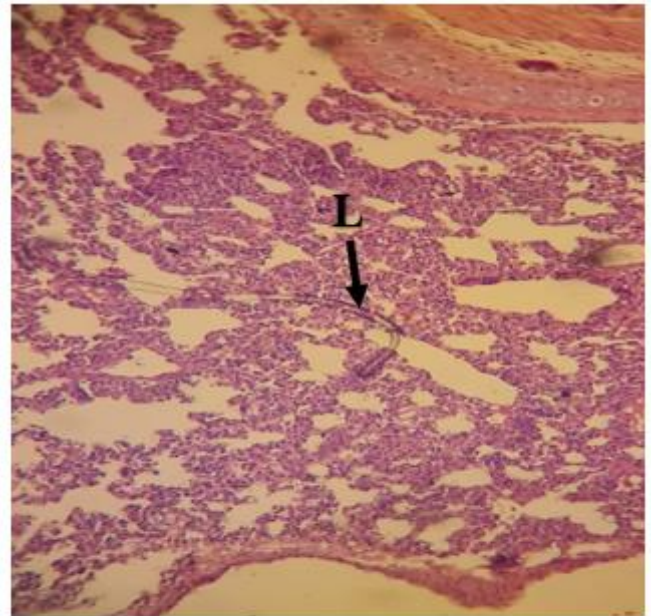


**Figure 4:** Lung section of infected group show Diapedesis of lymphocytes (DI), Leakage of plasma proteins (LE), Congestion of blood vessel and Aggregate of lymphocytes (AL), H&E 100X.

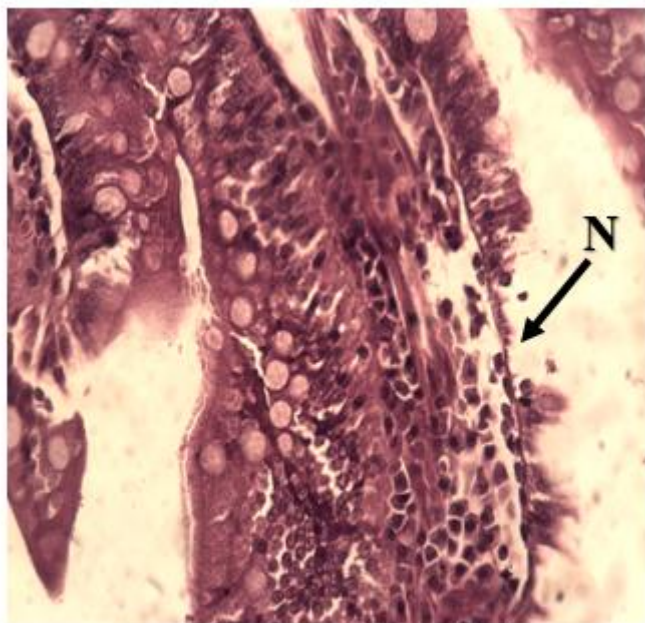
Detection of some Physiological and Histological changes in laboratory rabbits infected with *Necator americanus* parasite



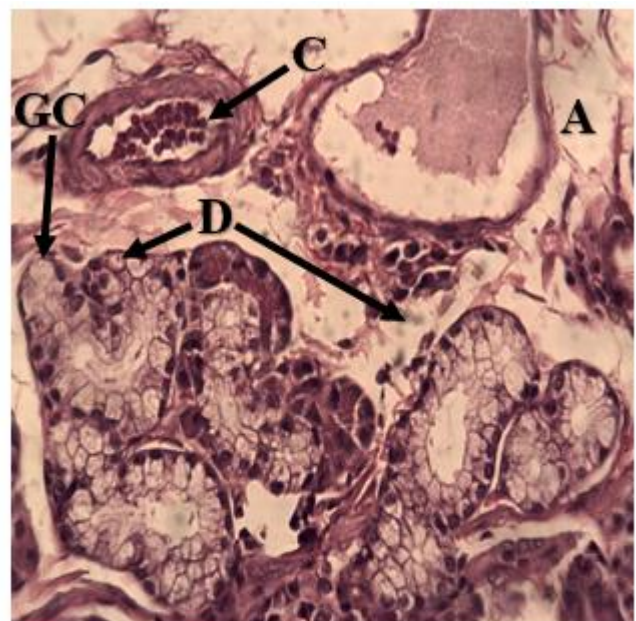
**Figure 5:** Lung section of infected group show Degeneration of alveolar cell (D) and Necrosis of alveolar cells (N), H&E 400X.



**Figure 6:** Lung section of infected group show Larva of worm (L), H&E 100X.



**Figure 7:** Intestine section of infected group show Necrosis in mucosa layer (N), H&E 400X.



**Figure 8:** Intestine section of infected group show Degeneration in Brunner glands and lamina propria (D) and Ghost cells (GC), Congestion of blood vessel (C), Atrophy of epithelial layer (A), H&E 400X.

**CONCLUSION**

1.The occurrence of significant differences in the levels of lipid profiles (cholesterol and HDL) and non- significant differences of triglycerides in infected group compared with control group.

2.The current study recorded significant differences in GOT and Iron, and non- significant differences in GPT of infected group compared with control group.

## Detection of some Physiological and Histological changes in laboratory rabbits infected with *Necator americanus* parasite

3. The occurrence of changes in histological sections of liver, lung and intestine of infected group compared with control group.

### ACKNOWLEDGMENTS

We appreciate Dr. Lamia Ahmed Mahal's assistance in the histology identification of infected group organs.

### REFERENCES

- I. Al-Ammash, M.S.J. 2012. Study the effect of some plants extracts and metronidazole drug on *Giardia lamblia* in mice *Balb/c*. M.Sc. Thesis, Col. Sci., Univ. Tikrit, 165pp.
- II. Albonico, M., Stoltzfus, R.J., Savioli, L., et al. 1998. Epidemiological evidence for a differential effect of hookworm species, *Ancylostoma duodenale* or *Necator americanus*, on iron status of children. *Int J Epidemiol*, 27: 530-7.
- III. Bancroft, J. and Stevens, A. 1987. Theory and practice of histological technique. *Edinburgh and London*, pp: 482-502.
- IV. Bouchery, T., Moyat, M., Sotillo, J., Papayannopoulos, V., Loukas, A. and Harris, N.L. 2022. Hookworms Evade Host Immunity by Secreting a Deoxyribonuclease to Degrade Neutrophil Extracellular Traps. *Cell Host & Microbe* 27: 277-289.
- V. Bundy, D.A., Chan, M.S., Savioli, L. 1995. Hookworm infection in pregnancy. *Trans. R. Soc. Trop. Med. Hyg.*, 89: 521-522.
- VI. Chang, T., Jung, B., Sohn, W., Hong, S., Shin, H., Ryoo, S., Lee, J., Lee, K.H., Khieu, V., Huy, R. and Chai, J. 2022. Morphological and Molecular Diagnosis of *Necator americanus* and *Ancylostoma ceylanicum* Recovered from Villagers in Northern Cambodia. *Korean J. Parasitol*, 58(6): 619-625.
- VII. Cleophas, T.J. and Zwinderman, A.H. SPSS for starters and 2nd levelers. 2<sup>nd</sup> edn. Springer Cham Heidelberg, New York, 2016; 375pp.
- VIII. Haas, W., Haberl, B., Idris, S. I., Kallert, D., Kersten, S. and Stiegeler, P. 2005. Behavioural strategies used by the hookworms *Necator americanus* and *Ancylostoma duodenale* to find, recognize and invade the human host. *Parasitol. Res.* 95: 30-39.
- IX. Hossain, M. and Bhuiyan, J.U. 2016. Hookworm Infection: A Neglected Tropical Disease of Mankind. *Journal of Infection and Molecular Biology*, 4(2): 24-42.
- X. Hotez, P.J., Brooker, S., Phil., D., Bethony, J.M., Bottazzi, M.E., Loukas, A. and Xiao, S. 2004. Hookworm Infection. *The new england journal of medicine*, 351:799-807.
- XI. Lwambo, N.J., Bundy, D.A., Medley G.F. 1992. A new approach to morbidity risk assessment in hookworm endemic communities. *Epidemiol Infect.*, 108: 469-81.
- XII. Nelson, D.L., Cox, M.M. and Hoskins, A.A. 2020. *Lehninger principles of biochemistry*. 8<sup>th</sup> edn., W. H. Freeman and company, New York. 1248pp.
- XIII. Olsen, A., Magnussen, P., Ouma, J.H., Andreassen, J., Friis, H. 1998. The contribution of hookworm and other parasitic infections to haemoglobin and iron status among children and adults in western Kenya. *Trans. R. Soc. Trop. Med. Hyg.*, 92: 643-649.
- XIV. Pagana, K.D., Timothy, R.N., Pagana, J. and Theresa Noel Pagana, T.N. 2022. *Mosby's Manual of Diagnostic and Laboratory Tests*, 7<sup>th</sup> edn. Mosby, Elsevier. 1200pp.
- XV. Penman, I.D., Ralston, S.H., Strachan, M.W.J. and Hobson, R.P. 2022. *Davidson's Principles and Practice of Medicine*. 24<sup>th</sup>edn. Elsevier. 1357pp.
- XVI. Pierce, D., Merone, L., Lewis, C., Rahman, T., Croese, J., Loukas, A., McDonald, M., Giacomini, P. and McDermott, R. 2019. Safety and tolerability of experimental hookworm infection in humans with metabolic disease: study protocol for a phase 1b randomised controlled clinical trial, *BMC Endocrine Disorders*. 19(136): 1-11.
- XVII. Pratt, D.S. and Kaplan, M.M. 2000. Evaluation of abnormal liver enzyme – result in asymptomatic patients. *N. Engl. Med.*, 342: 1266-1271.
- XVIII. Roberts, L.S., Janovy Jr, J. and Nadler, S. 2013. *Schmidt and Robert's Foundations of Parasitology*. 9<sup>th</sup> edn., McGraw-Hill Co., Inc., USA, 678pp.
- XIX. Sabaa, T.A.E. 2021. Comparison of some Biological and Immunological effect associated with infections *Entamoeba histolytica* and *Giardia lamblia* for persons suffering from diabetes. College of Education for pure Science, University of Tikrit, Tikrit, 131pp.
- XX. Stoltzfus R.J., Chwaya, H.M., Tielsch, J.M., Schulze, K.J., Albonico, M. and Savioli, L. 1997. Epidemiology of iron deficiency anemia in Zanzibari schoolchildren: the importance of hookworms. *Am. J. Clin. Nutr.*, 65: 153-159.
- XXI. Uduchi, I.O., Okolie, N.J.C., Opara, A.U., Ilo, C.E. Emmanuel Obeagu, I. and Samuel Ogenyi, I. 2022. Curative and Toxic Effects of Selected Medicinal Plants on Internal Organs of *Rattus albus* Experimentally Infected with Human Intestinal Parasites. *Journal of Advances in Medical and Pharmaceutical Sciences*, 24(4): 28-43.
- XXII. Umbrello, G., Pinzani, R., Bandera, A., Formenti, F., Zavarise, G., Arghittu, M., Girelli, D., Maraschini, A., Muscatello, A., Marchisio, P. and Bosis, S. 2021. Hookworm infection in infants: a

## Detection of some Physiological and Histological changes in laboratory rabbits infected with *Necator americanus* parasite

case report and review of literature. Italian Journal of Pediatrics, 47(26): 1-5.

- XXIII. Wakelin, D. Helminths: Pathogenesis and Defenses. 1996. In: Medical Microbiology. 4th edn. Baron, S. (eds.) Galveston (TX): University of Texas, Medical Branch at Galveston; Chapter 87.
- XXIV. WHO, 1991. Basic laboratory methods in medical parasitology. World Health Organ., Geneva, 114pp.
- XXV. Wilkinson, M.J. Wells, C. and Behnke, J.M. 1990. *Necator americanus* in the mouse: histopathological changes associated with the passage of larvae through the lungs of mice exposed to primary and secondary infection. Parasitol. Res.,76: 386-392.
- XXVI. Williamson, A.L., Brindley, P.J., Knox, D.P., Hotez, P.J. and Loukas. A. 2003. Digestive proteases of blood-feeding nematodes. Trends Parasit., 19: 417–423.